

# Surgical Treatment of Erectile Dysfunction

Eduardo B. Bertero, MD and Dimas L. Antunes, MD

Department of Urology, Section of Sexual Medicine, Hospital do Servidor Publico Estadual, São Paulo, SP, Brazil

DOI: 10.1002/smrj.60

## ABSTRACT

**Introduction.** Currently, oral pharmacotherapy is the dominant treatment for erectile dysfunction.

**Aim.** The aim of this article is to give an up-to-date summary of the possibilities of surgical therapy.

**Methods.** A search of the literature over the last decade was performed. Relevant papers and guidelines on the topic were reviewed and included.

**Main Outcome Measure.** We evaluate therapy options, such as penile vein surgery, arterial revascularization, and penile prosthetics.

**Results.** Vein surgery has faded into total insignificance due to the efficiency of oral and intracavernous therapeutics, and because of the known pathophysiology of corporal veno-occlusive dysfunction and the disappointing long-term results published in the literature. Penile revascularization surgery is performed today only in very limited number of patients with strict selection criteria such as age and exclusion of vascular risk factors.

**Conclusions.** Penile prosthetics is the only surgical therapy option maintaining its significance as a cure for erectile dysfunction. There are convincing long-term results with a high degree of patient and partner satisfaction, high patient acceptance, and a good functional durability of the mostly three-piece inflatable devices. **Bertero EB and Antunes DL. Surgical treatment of erectile dysfunction. Sex Med Rev 2015;3:316–327.**

**Key Words.** Vasculogenic Erectile Dysfunction; Vascular Surgical Procedures; Penile Prosthesis; Impotence; Penile Implants; Erectile Dysfunction Treatment

## Introduction

The aim of this article is to collect data on surgical treatment of erectile dysfunction (ED) based on passed, recent state-of-the-art consensus reports, and published articles in peer-reviewed journals.

### Venous Ligation Surgery

The majority of venous procedures to treat ED was developed before our current understanding of the pathophysiology of corporal veno-occlusive dysfunction (CVOD) [1]. It is consensus today that CVOD is a result of endothelial dysfunction and damage to the penile smooth muscle rather than “excessive drainage from veins” as thought decades ago. Today we know that such alterations will not be affected by surgical ligation of extracorporeal veins [2]. For example, hypercholesterolemia and

arteriosclerotic-induced ischemia can be associated with alterations in the fibroelastic components of the trabeculae [3]. Table 1 lists all published venous ligation procedures described [4]. Based on the 3rd International Consultation on Sexual Medicine, “[p]enile venous reconstructive surgery performed with the intent to limit the venous outflow of the penis are not recommended” [5]. Regarding surgical outcome, too many unsolved controversies exist, and universal diagnostic criteria for patient selection as well as operative technique selection have not been unequivocally established [2].

### Penile Revascularization

In 1973, the Czech surgeon, Michal et al. described the first penile revascularization surgery, and this technique has been named the Michal I

**Table 1** Published venous ligation procedures described

CVOD surgery and procedures
Superficial dorsal vein ligation
Deep dorsal vein ligation/excision
Crural vein ligation
Crural plication/ligation
Deep dorsal vein arterialization
Cavernosal vein arterialization
Spongiolysis
Pericavernosoplasty
Therapeutic embolization
Combinations of the above
Extraperitoneal laparoscopic penile vein ligation

CVOD = corporal veno-occlusive dysfunction

procedure [6]. Years later, the direct anastomosis to the corpora was abandoned, and microsurgical techniques made possible the anastomosis from the inferior epigastric artery (IEA) to dorsal vessels (dorsal vein and artery). It is very difficult to make comparisons of results and to achieve consensus on the literature, especially because of the heterogeneity and complexity of the study population.

#### Patient Selection and Workup

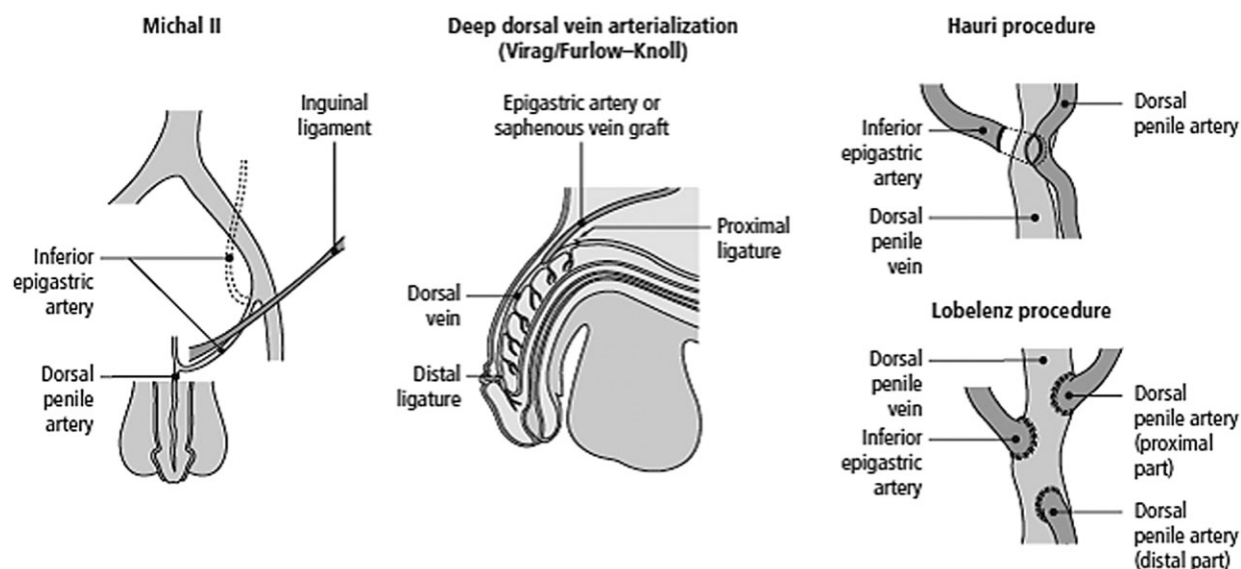
The ideal patient for penile revascularization using microsurgical technique is a young man with a history of focal endothelial dysfunction and an absence of systemic endothelial dysfunction. The typical case is a man less than 50 years of age, with a past of pelvic blunt trauma with injury to the pudendal artery. The distal internal pudendal

artery, common penile artery, and proximal cavernosal artery are particularly susceptible to injury given the fixed anatomic relationship to the ischiopubic ramus as it passes through Alcock's canal [7]. The extent and types of workup vary in different centers. However, the mainstay of the workup includes full examination, psychological evaluation, laboratory tests, color Doppler ultrasonography, dynamic infusion pharmacologic cavernosometry and cavernosography, and selective internal pudendal arteriography or digital subtraction angiography [8]. Some discrepancies between Doppler and arteriography have been shown and could diminish the number of real candidates for revascularization [9]. Men with known vascular risk factors, such as diabetes, hypertension, tobacco use, hypercholesterolemia, and evidence of neurological ED, psychiatric disorders, Peyronie's disease, premature ejaculation, and evidence of corpora-occlusive dysfunction, should be excluded.

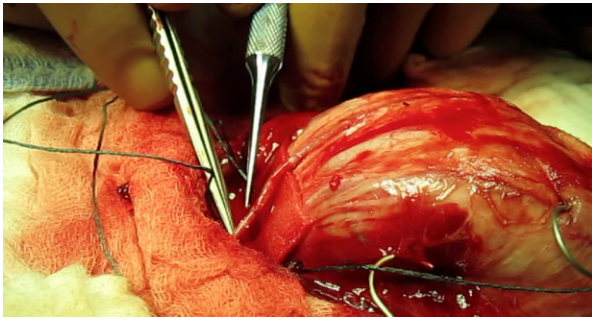
#### Types of Interventions and Rationale

Various techniques have been described, and the IEA is used to establish new arterial flow for most penile revascularization surgeries [10,11]. Currently, three surgical approaches are still in use, as depicted on Figure 1 [4]. These are the following:

1. Anastomosis of the IEA to the dorsal penile arteries (end-to-end or end-to-side).
2. Anastomosis of the IEA to the deep dorsal vein and deep dorsal artery (arterious-venous shunt).



**Figure 1** Three principal surgical approaches for penile revascularization in clinical use [4]



**Figure 2** End-to-end inferior epigastric artery and deep dorsal penile artery anastomosis

3. Anastomosis of the IEA to the deep dorsal vein with additional proximal and/or distal vein ligation.

Historically, the success of bypass grafting for coronary artery disease suggested bypassing obstructed arteries could restore normal erectile function in men suffering from arteriogenic ED. The aim of the surgery is to bypass the obstructed distal internal pudendal/common penile cavernosal arteries and deliver increased systolic perfusion pressure and blood flow from the donor IEA to the recipient dorsal penile artery. Ideally, the increased dorsal artery systolic perfusion pressure and blood flow will be communicated to the cavernosal artery via perforating branches between the dorsal penile artery and the cavernosal artery [4,6,12].

One of the most experienced urologists to perform such procedure, Irwin Goldstein, reportedly more than 1,500 cases, illustrates on Figure 2 an end-to-end IEA to deep dorsal artery anastomosis.

#### Outcome of Revascularization Procedures

There has been very few case series published in the literature since 2003. Most of these studies were limited by varying inclusion and exclusion criteria, short length of follow-up, and lack of validated success evaluation during follow-up [13]. The best validated instrument for subjective success evaluation is the International Index of Erectile Function (IIEF), which was not available before 1997 [14]. This may reflect the American Urological Association (AUA) and European Association of Urology (EAU) guidelines. The AUA says, “The efficacy of this surgery remains unproven and controversial, largely because the selection criteria, outcome measurements, and microsurgical techniques have not been objective

or standardized” [12]. The EAU statement says, “In young patients with pelvic or perineal trauma, surgical penile revascularization has a 60–70% long-term success rate. The lesion must be demonstrated by duplex Doppler study of the penis and confirmed by penile phacoarteriography” [13]. No comparative prospective, randomized studies exist for outcome evaluation.

One of the largest contemporary retrospective series is that of Kawanishi et al. [15]. Although published in 2004 and using the 1996 guidelines, this study on 51 men with arteriogenic ED stands out from other retrospective series in terms of objective outcome data reported by color Doppler duplex studies and a longer follow-up period. The patency of blood flow was assessed objectively by color flow duplex Doppler. The mean (standard deviation) subjectively estimated efficacy rate was  $85.9 \pm 6.3\%$  after 3 years and  $67.5 \pm 10.7\%$  after 5 years of follow-up. The objective estimated efficacy rate was  $84.9 \pm 7.3\%$  at 3 years and  $65.5 \pm 13.5\%$  after 5 years of follow-up.

In a retrospective, single-institution study on 71 men who underwent microvascular arterial bypass surgery with a mean follow-up of  $34.5 \pm 18$  months, the rigidity of the penis was assessed by an analog scale. Mean preoperative and postoperative penile rigidity measures with and without phosphodiesterase type 5 inhibitors (PDE5) were 41%, 77% and 71%, and 90.8%, respectively. The score increased on the IIEF from a mean of 35.5 to 56.2, and the *erectile dysfunction domain* increased from 14.8 to 23.8 after surgery [16].

The same study demonstrated treatment satisfaction as high, according to the Erectile Dysfunction Inventory of Treatment Satisfaction (EDITS) [16].

In one systematic review and meta-analysis published by Babaei et al., 46 studies were included and involved patients who have undergone some form of penile revascularization. The overall success rate was about 50% after a mean follow-up of 50 months, of whom 30% had experienced spontaneous erections and 20% had pharmacologically induced erections (partial response). Long-term failure had been reported in about 50% of men. Moreover, there was a strong correlation between success and the elapsed time from the operation (odds ratio [OR], 3.6; 95% confidence interval [CI], 2.8–5.6). The success rate in all series tended to diminish as follow-up period increased. Finally, the impact of age was greatest; patients younger than 30 years old showed better success rate than the older ones (OR, 37; 95% CI,

**Table 2** Data on various series reported on penile revascularization procedures [4]

Study	Number of patients	Procedure	Age	Follow-up (range)	Success (unassisted)	Success (assisted)	Overall intercourse	Notes
Depalma 1997	12	Dorsal artery	n/a	33 (12–48)	27%	n/a	n/a	
Lukkarinen 1997	24	V5 6 Hauri 4 F-F14	n/a	n/a	46%	33%	77%	No differences in outcomes by age at operation
Manning 1998	62	Virag 7 Hauri 55	48 (19–70)	41 (18–72)	34%	20%	54%	Patency: 92%
Manning 1998	42	DDVA (Mannheim)	n/a	n/a	31%	26%	57%	<50 years, 83% success
Vardi 2002	61	n/a	20–50	60 (24–120)	48%	n/a	n/a	CVOD success: 64%, Art. Dx. success: 44%
Kawanishi 2004	51	Hauri 26 Furlow 23	21–49	36–60	n/a	n/a	85.3% (3 years) 65.5% (5 years)	No difference between techniques
Munarriz 2009	71	Dorsal artery	18–54	8–80	77%	90.8%	n/a	Improves depression and overall satisfaction

CVOD = corporal veno-occlusive dysfunction

2.2–6.4;  $P = 0.001$ ) [8]. Table 2 summarizes various series on penile revascularization.

### Complications

Complications occur in up to 25% of patients after penile revascularization [5–11]. Glans hyperemia is the most common complication after these procedures. Inguinal hernia and postoperative hematoma have occurred in up to 25% of patients as well [17]. A traumatic disruption of the anastomosis is possible within the first few weeks following surgery [7]. Other possible complications include decreased penile sensation secondary to injury of the dorsal nerves, penile pain, and loss of penile length. Munarriz et al. reported diminished penile length in 20 of 71 men and decreased penile sensation in 18 of 71 [16]. More recently, there has been a case of penile artery shunt syndrome reported due to an aberrant obturator artery arising from the donor IEA. The patient still suffered ED despite patency of the anastomosis [18].

### Penile Implant Surgery


The introduction of PDE5 inhibitors into the market in 1998 initially caused a significant drop in implant rates, but in more recent years a constant increase has been noted. Here are highlighted the key points that involve the types of penile prosthesis, patient selection, technical aspects of implants procedures, pre- and postoperative care, operative complications, and results on patient and partner satisfaction.

### Types of Penile Prosthesis

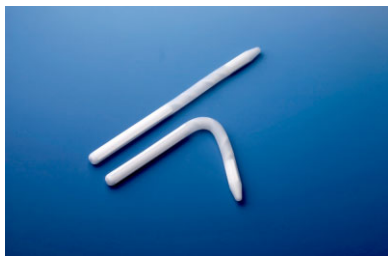There are two types of penile prosthesis: inflatable and non-inflatable implants. Both of them have

their pros and cons, but currently the inflatable penile prosthesis (IPP) is used more often in North America and Europe than the non-inflatable and there is a trend toward the use of the IPP in the Southern hemisphere. Analyzing case log data of penile prosthesis implanted by (re)certified urologists from the American Board of Urology from 2003 to 2012, Oberlin and colleagues observed that the proportion of the IPP compared with malleable prosthesis increased twelvefold over these 10 years [19].

Non-inflatable penile prostheses may be referred to as semirigid rod or malleable prosthesis. They consist of a pair of spiral wire core with a silicon or polyurethane jacket, but there are models such as the AMS Spectra™ (Figure 3), that are categorized as mechanical devices once; instead of a wire, they have articulated segments (balls and socket joints) of polyethylene that can be held together by a central spring. This design provides positional memory, allowing the prosthesis to remain concealed when not in use, yet rigid during intercourse. The Coloplast Genesis™ (Figure 4) also has a hydrophilic coating that



**Figure 3** AMS Spectra™



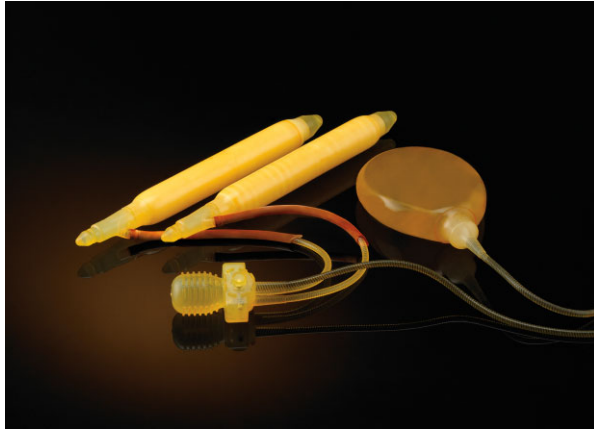
**Figure 4** The Coloplast Genesis™

allows the surgeon to maintain the device preparation with their own antibiotic. Other examples of semirigid penile prostheses worldwide are Jonas (ESKA) Prosthesis (Germany), Virilis I and II implants (Italy), Silimed Penile Prosthesis (Brazil), HR Penile Prosthesis (Brazil), Shah Implant (India), and Promedon Tube Prosthesis (Argentina). The models of these prostheses usually have a limited range of length and diameter sizes but most of them are trimmable and come with rear tip extenders to add length to the proximal cylinder end. Non-inflatable prostheses are usually cheaper than the inflatable ones, and their implant procedure, which can be done by a subcoronal, infrapubic, or scrotal incision, is easier because there is no need to place a reservoir or a pump. It can be an option for physically handicapped patients with finger or hand dexterity issues, muscle fatigue, or limited reach and range of mobility. On the other hand, as malleable penile prosthesis results in a firm penis, which may be manually placed in an erect or “flaccid” state, it can provide difficulty with concealment, some patient discomfort, can make urological endoscopic procedures (e.g., transurethral resection of the prostate [TURP], ureteroscopy) more challenging, and may cause deterioration and thinning of penile flesh over the long term [20].

The IPPs were developed to simulate the normal erection, and most of the recent discussions, researches, studies, and manufacture improvements have been directed toward this kind of prosthesis. They consist of a pair of cylinders implanted in the corpora cavernosa connected to a pump implanted in the scrotum. When the pump is squeezed and released several times, the cylinders are filled with sterile solution, simulating the corpora cavernosa blood filling during physiologic erection. There are two types of inflatable devices available: two-piece and three-piece prostheses, and the difference between them is the compartment where the saline solution is stocked during

the flaccid state. While two-piece devices have a small reservoir in the end of each cylinder or attached to the pump, the “third” element of the three-piece prosthesis is its bigger reservoir that is connected to the pump but is placed somewhere else, usually in the retrovesical space or within the peritoneal cavity. Hence, the rigidity and girth reached by the second are usually better, as well as the difference in appearance of the penis between the flaccid and erect stages. In the United States, there are two IPP manufacturers: Coloplast (Minneapolis, MN) and American Medical Systems (AMS) (Minnetonka, MN). The AMS Ambicor™ is a two-piece prefilled and pre-connected IPP consisting of a pair of cylinders and a pump composed of silicon elastomers. The cylinders and pump are pre-connected during the manufacturing process, and the system is filled with sterile saline. After a few squeezes, the pump transfers the solution from small reservoirs located at the end of each cylinder into each cylinder shaft, thereby causing an erection.

The three-piece IPP manufactured by the AMS has three variations of the AMS 700™ series: the AMS 700™ LGX, AMS 700™ CX, and AMS 700™. The difference is the cylinders design, but all of them are coated with parylene, which diminishes the risk of aneurysmal dilatation. The CXR has a narrow base and comes in shorter lengths than the CX, and both of them have a three-layer design consisting of an inner layer of elastic silicon, a middle layer of woven Dacron-Lycra, and an outer layer of silicon. The inner layer fills with fluid to provide rigidity, the middle layer permits controlled expansion of the cylinders, and the outer one allows for capsule formation around the prosthesis. In the CX and CXR, the middle layer is woven unidirectionally, permitting girth, but not length expansion. While AMS 700™ CX may have satisfactory results in all subsets of patients, the CXR is more appropriate for patients who have significant scarring of the corpora cavernosa (e.g., reimplant after previous removal of an infected prosthesis, extensive Peyronie’s disease, after priapism) due to its narrower cylinders, which requires dilatation of the corpora cavernosa to only 10 mm. The Dacron-Lycra middle layer of the AMS 700™ LGX has a bidirectional weave that permits both girth and length expansion of the cylinders with up to 20% elongation, depending on the patient’s anatomy. However, the LGX model is not appropriate for patients with associated Peyronie’s disease because they need greater stiffness than is provided by this



**Figure 5** AMS 700 InhibiZone™

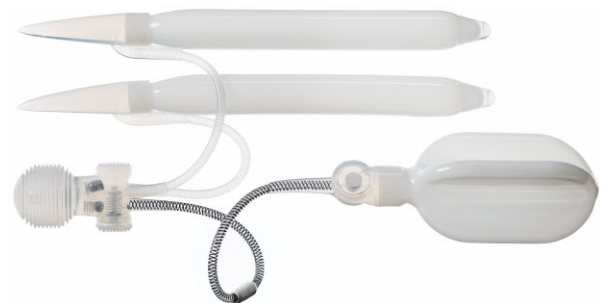prosthesis. The AMS 700™ series penile prostheses also feature other design improvements, and some models are available with or without some of these features: pre-connected cylinders and pump to ease the implant procedure; Conceal™ low profile reservoir parylene coated to enhance durability; broad range of Snap-Fit™ Rear Tip Extenders available in 0.5-cm increments, ranging from 0.5 to 7.5 cm, to provide custom fit for patients; MS (Momentary Squeeze) pump with one-touch button designed for easy deflation and lockout valve to resist auto-inflation. This line of prosthesis also offers a remarkable feature: the InhibiZone™, which is an antibiotic treatment (Figure 5). These are the only antibiotic-coated IPPs on the market. The surface of these devices, which comes in contact with the adjacent tissue, are impregnated with quantifiable doses of rifampicin and minocycline that elute into the surrounding area of the prosthesis inhibiting bacterial growth after surgery, particularly for *Staphylococcus epidermidis* and *Staphylococcus aureus*. Both drugs elute initially at high rates, with significant decrease in rifampicin and minocycline after 1 and 7 days, respectively [21,22].

The three-piece IPP manufactured by Coloplast is called Titan® and has two versions: the Titan® OTR-One-Touch Release (Figure 6) and Touch. They have a similar design compared with the previously described AMS 700™, but there are some differences. First, the Coloplast implants are made based on an inert aromatic polyurethane polymer called Bioflex™, which, compared with silicon, has increased abrasion resistance and higher tensile strength. The Titan's reservoir has a cloverleaf configuration that can be easier to install than the previous version. The

input tubing exits the cylinder at a zero-degree angle that facilitates its installing, and the cylinders, which are pre-connected to the pump, are available in a narrow-base shape. In the first quarter of 2014, the Coloplast released a smaller version of the One-Touch Release® pump, the Touch®, whose mechanism permits easy deflation of the device and has a Lock-Out™ valve to prevent auto-inflation. Finally, the Coloplast devices also differ from the AMS devices in the method developed to reduce penile prosthetic infection. Instead of a predetermined mix of antibiotics, Coloplast prostheses have an intensely hydrophilic coating whose increased lubrication has been shown to decrease bacterial adherence in vitro. This hydrophilic coat also absorbs antibiotics from a soaking solution and can elute surrounding tissues over 24–72 hours to decrease infection. The antibiotics chosen to coat the implant pieces may vary between centers, but some advocate a combination of gentamicin and bacitracin, or gentamicin and rifampin [21–23].

#### *Patient and Implant Selection*

The surgical implantation of a penile prosthesis is regarded as a third-line therapy for ED by the majority of consensus, which means that the patient has already been submitted to other therapies that failed, that they were offered and rejected by the patient, or that there are contraindications for other therapies. These therapies may include oral therapy with PDE5 inhibitors, vacuum erection devices, shockwave therapy, intracavernous injections (alprostadil, papaverine, phentolamine, and their combinations), and intraurethral alprostadil. Patients eligible for penile implant should be assessed with a full systemic medical, psychological, and sexual history, and he and, when possible, his partner should be informed of the types, management, and costs of available



**Figure 6** Coloplast Titan OT

prostheses; possibility and consequences of infection and erosion, mechanical failure, and resulting reoperations; differences from the normal and flaccid and erect penis, including penile shortening; and potential reduction of effectiveness of other therapies if the device is subsequently removed, once the space previously occupied by the cylinders is partially filled with proliferating scar tissue [24–27]. It is a cardinal principle that the patient has a realistic expectation of his penile prosthesis, so it is important to warn him that the sensitivity of the penis, sexual drive, and ejaculatory abilities are for the most part unchanged following the procedure, and that the post-implant size of his penis will invariably be slightly shorter than his natural erection when he was fully potent. In addition, unlike physiologic erection, the prosthetic erection does not result in an increase in the size of the glans. Whereas the girth of the penis may be greater than natural erection particularly with three-piece devices, it should be emphasized to the patient that the girth, not the length, is responsible for penile rigidity, which produces maximum sexual satisfaction in the female. In any case, if patients are disappointed postoperatively with their penile length, they can be advised that daily inflation of the prosthesis may produce corporal dilatation, and surgical replacement with longer cylinders may be possible later [28]. The candidates for a penile prosthesis implantation should be in a good general health and psychologically stable and fully informed (with an informed consent for surgery, if available). For a good medical assessment of patients' conditions, there are many elements that may be used, such as penile color Doppler sonography with intracorporal pharmacologic injection; nocturnal penile tumescence test, especially when it is assumed that the patient's ED is predominantly psychogenic; validated questionnaires to objectively assess severity of ED; and subsequent postoperative outcomes, such as IIEF and EDITS. Finally, an important issue in selecting eligible patient for penile implants is the early detection of at least temporary contraindications. Prosthetic surgery should not be performed in the presence of systemic, cutaneous, or urinary tract infection (UTI), which might result in bacterial seeding in surrounding areas of the devices and consequently its extraction. A urine culture is mandatory in all patients, and those who have UTI, lesions in the genital area, and other local infections or systemic infections should defer surgery until this issue is resolved. It is important to evaluate the lower

urinary tract in order to avoid untoward events (e.g., UTI, urinary retention, difficulty inserting a catheter) and to detect conditions that would require previous approach, such as a transurethral bladder neck incision or artificial urinary sphincter placement for post-radical prostatectomy patients [5]. Diabetes mellitus is known to be not only a risk factor for severe ED that may require penile implants for treatment, but also a risk factor for the development of infections in various clinical scenarios [29,30]. Nevertheless, despite some studies in the past suggesting that diabetes, elevated hemoglobin A1C or fasting blood sugar, or insulin dependence were risk factors for penile implant infection and their control were necessary to reduce its risk, the literature fails to demonstrate a consistent benefit [31,32].

Finally, after selecting an eligible patient for penile prosthesis, the last step toward the surgical implant is to choose the type of device that best fits the patient. This decision should be taken with both the physician and the patient, and is usually based on the urologist's comfort with surgical approach, assessment of body habitus, presence of associated conditions (e.g., Peyronie's disease, spinal cord injury), manual dexterity of the patient, and overall cost. In most industrialized countries, if cost is not a limiting factor (e.g., reimbursement by third parties), the three-piece IPP is considered the "gold standard," accounting for 70% of implants in the United States [19], while 20% are two-piece (Ambicor™) and 10% are semirigid rods. This is because, despite its somewhat more complex insertion as it requires the placement of the two cylinders, the pump and the reservoir into the abdominal cavity, the three-piece implant gives the best rigidity and flaccidity since it fills every part of the corporal bodies, and its bigger capacity reservoir permits a better emptying of the cylinders avoiding erectile tissue deterioration, as witnessed with self-contained or two-piece devices with no reserve fluid volume [20]. For patients with complex anatomic issues, such as neobladder after cystectomy or kidney transplant, the surgeon may consider placing a simpler device than the three-piece prosthesis to avoid intra-abdominal reservoir, such as a two-piece prosthesis, or choose an alternative site to place the reservoir instead of behind the pelvic bone in the space of Retzius (e.g., intra-abdominal) [33]. For this scenario, Coloplast manufactures a reservoir equipped with a lockout valve to prevent transfer of fluid to the cylinders once the reservoir is placed in different locations that would normally cause auto-inflation

(e.g., anterior to transversalis fascia and posterior to the abdominal muscles) [34]. If there is a lack of manual or mental ability to manipulate inflatable devices or if the patient's partner cannot manipulate the pump, malleable penile prosthesis may be an option. As patients with spinal cord injuries have been more prone to have erosion of semirigid rod cylinders through the glans because of cylinder pressure and the absence of cutaneous sensation, some urologists recommend inflatable implants for spinal cord injury even if they are used only to facilitate condom catheter urinary drainage [35]. In patients with severely scarred corpora, if a three-piece was chosen, AMS 700™CXR or Titan OTR® narrow-based devices should be used. In contrast, AMS 700™ LGX should be avoided in patients with Peyronie's disease.

#### *Preoperative Considerations*

For a few days prior to the surgery, patients are advised to shower with antibacterial soap, and they should be admitted to the hospital either the evening before or the morning of the operation in order to minimize the risk of contracting infections from hospital contamination. The urine culture should be negative at the time of the surgery [24,36], but routine urine culture is not performed by 40% and 50% of the Sexual Medicine Society of North America and International Society of Sexual Medicine members, respectively [37]. It is advisable to shave the operative area immediately prior to surgery; small cuts in the skin may become infected if shaving is done earlier. Following, the skin should be scrubbed with iodopovidone or chlorhexidine preparations. Antibiotic prophylaxis is a well-established concept among prosthesis surgeons in order to promote implant survival through a broad-spectrum coverage against both Gram-positive and Gram-negative agents [38–40]. Intravenous administration of the first dose of antibiotic should be completed at least 1 hour before the skin incision to ensure adequate serum concentrations at the time of the surgery, but oral regimens may be used [41]. Nevertheless, it has been particularly difficult to try to find a compromise about which antibiotic regimen to be used [37,42]. The most common germs involved are the Staphylococcus species and enteric bacteria, and some commonly used antibiotic regimen are intravenous vancomycin plus gentamicin, vancomycin plus rifampicin, and cephalosporin plus gentamicin, with or without oral fluoroquinolone given the day before the procedure [24,36,37,41–43]. A

“no-touch” technique has been described and has been proven to decrease the risk for IPP infections in up to 0.46% when associated to coated implants [43].

#### *Operative Considerations*

Penile prosthesis implantation is usually performed under general, spinal, or epidural anesthesia but has been performed using local anesthesia for penile block with or without pudendal block, particularly for malleable devices that do not require an abdominal manipulation (e.g., for the reservoir) [36,44,45]. This penile block is usually done with 25 cc of 1% lidocaine instilled into either corpus cavernosum after a tourniquet is placed around the base of the penis (and released after 1 minute to diffuse the anesthetic into proximal portion of the corpora). As cited before, non-inflatable prosthesis can be implanted by a subcoronal, infrapubic, or scrotal incision. Some consider the distal penile approach the best option for insertion of semirigid prostheses; when this incision heals well, it allows for complete dilatation and facilitates rod placement [5]. For IPP implantation there are two main approaches—penoscrotal and infrapubic—and there is no evidence that one is better than the other [46], so the choice must be made based on the patient's anatomy, surgical history, and surgeon's experience. Nevertheless, assessing intraoperative data from 256 IPPs placed by high-volume surgeons from March to July 2012, Trost and colleagues observed that the trans-scrotal approach was performed most commonly (80% of the cases) [47]. In this study, it was also shown that, compared with infrapubic, trans-scrotal placement resulted in a longer total prosthesis (22.3 cm vs. 20.6 cm,  $P < 0.0001$ ), increased proximal dilation (10.1 cm vs. 8.6 cm,  $P < 0.0001$ ), longer Rear-Tip Extenders (1.9 cm vs. 1.2 cm,  $P < 0.0001$ ), and larger reservoir fill volume (79 cc vs. 71 cc,  $P = 0.0003$ ), but no differences were noted in distal measurements or ability to place the reservoir in the space of Retzius. The transverse penoscrotal approach should be preceded by urethral catheterization to empty the bladder and facilitate urethral identification. It provides an excellent exposure, affording proximal crural exposure as far as the ischial tuberosities if necessary, avoids dorsal nerve injury, and permits direct visualization of pump placement, and may achieve increased proximal dilatation [47]. However, with this approach, the reservoir is blindly placed into the retropubic space, which can be a problem in patients with a history of major



pelvic surgery (e.g., radical cystectomy). On the other hand, the infrapubic approach has the advantage of reservoir placement under direct vision, but the implantation of the pump may be more challenging, and patients are at a slightly increased risk of dorsal nerve injury [13].

### *Postoperative Management*

Most patients are discharged on the first day after the procedure, and they should be informed that some scrotal ecchymosis and swelling are common, and that scrotal hematoma, if it forms, usually slowly resolves without operative intervention. Pain is usually more than other genital procedures without prosthetic components. Patients with inflatable devices must be instructed to start activating and deactivating the implant as soon as their local pain allows. First follow-up visit should take place in 7–10 days, and the second appointment in approximately 6 weeks, when sexual activity starts to be allowed. As it was mentioned, validated instruments, such as IIEF and EDITS, may be used to objectively assess the outcomes. For patient's complaint of lack of adequate engorgement of the glans during the activation of inflatable devices, it has been reported that there is a beneficial effect on implant-assisted intercourse with the use of oral sildenafil [48] or intraurethral alprostadil [49].

### *Complications*

There are various possible complications associated with penile prosthesis implantation, and they can occur during the procedure itself (intraoperative complications) or after the implantation (postoperative complications). Intraoperative complications include proximal and distal perforation of the tunica albuginea during dilatation of corpora cavernosa, which can be handled with a primary approach or lead to abortion of the procedure to avoid prosthesis infection; urethra injuries, which can be managed with primary urethral repair and suprapubic cystostomy [50]; and displacement of reservoir or bladder injury [51,52]. Postoperative complications may be related to mismeasurement of cylinder sizes, unnoticed injuries to surrounding tissues during the implantation of the prosthesis' elements, or even capsular contraction, leading to erosion of a component (e.g., distal cylinder erosion or extrusion), "S-shaped" penis deformity, and supersonic transporter deformity [51,53–55]. But the most common complications necessitating reoperation are infection and mechanical dysfunction [5].

While malleable penile prostheses virtually do not have any mechanical failure, there has been a concern about this complication for inflatable implants among urologists, manufacturers, patients, and his partners. If in the past there were high rates of IPP mechanical dysfunction, several technical modifications, such as those cited before for the most commonly used three-piece prosthesis, resulted in mechanical failure rates of less than 5% after 5-year follow-up [56,57]. Overall mechanical survival of three-piece prostheses range 81–94, 68–89, and 57–76% at 5, 10, and 15 years, respectively, in some studies [58]. For instance, the introduction of a lockout valve in the reservoir stem by Coloplast resulted in a 1.3% of partial spontaneous inflation (auto-inflation), compared with an 11% rate in historical controls [34]. If mechanical problems in an inflatable device develop after surgery, there is a trend to remove and replace the entire device. Other common mechanical failures are tubing fracture, cylinder or reservoir leak, cylinder aneurysm, or connector disruption. Most urologists consider that replacing the entire device will give the patient added longevity in all parts [24]. Nevertheless, pseudo-malfunction of IPP has been related, and it should be diagnosed in order to avoid reoperations [59].

Finally, the most significant postoperative complication associated with implant surgery is periprosthetic infection. Infection in the space around a penile prosthesis rarely leads to seriously ill patients, but eradication of the infection usually requires complete removal of the device, and subsequent penile prosthesis reimplantation is difficult due to the scarring of the corporeal smooth muscle, which leads to decreased penile length and girth and challenging cylinder implantation. Fortunately, careful surgical technique with proper antibiotic prophylaxis against Gram-positive and Gram-negative bacteria reduces infection rates to 2–3% with primary implantation in low-risk patients. The infection rate may be further reduced to 1–2% by implanting an antibiotic-impregnated prosthesis (AMS InhibiZone™) or hydrophilic-coated prosthesis (Coloplast Titan™) [60–63], and rates as low as 0.46% have been described [43]. Risk factors related to prosthesis infection are revision surgery, impaired host defenses (spinal cord injury, diabetes mellitus, immunosuppression), and penile corporal fibrosis. Instead of complete removal of the prosthesis in an infection scenario, a salvage protocol can be followed. Introduced in 1996 by Brant and Mulcahy, this procedure involves the removal of the infected

device, plentiful wash of the implant spaces with a series of antiseptic solutions, and implantation of a new prosthesis. Updated series with this procedure have shown success rate as higher as 84% [64]. Recently, another protocol has been reported with the use of a novel temporary synthetic high-purity calcium sulfate (SHPCaSO<sub>4</sub>) component that acts as a “spacer” at the time of removal of an infected prosthesis while providing constant delivery of local antibiotic elution to the infected area [65].

The majority of reoperations are secondary to mechanical failure and combined erosion or infection. Reoperation rates for infectious and noninfectious failure are equivalent between the semirigid and inflatable penile prostheses [66]. In this scenario, the severe corporeal fibrosis, particularly after removal of prosthesis after infection, may turn dilatation extremely challenging and may require the use of special tools and techniques [67]. Overall, 93% of cases are successfully revised, providing functioning penile prosthesis [13].

#### Results of Penile Prosthesis Surgery

Among the treatment options for ED, prosthesis implantation has one of the highest satisfaction rates (92–100% in patients and 91–95% in partners) based on appropriate consultation through validated instruments, such as IIEF, EDITS, and other quality-of-life questionnaires (e.g., Quality of Life and Sexuality with Penile Prosthesis) [13,68]. The rapid ability to produce an erection and consistent excellent rigidity are two major factors contributing to this high level of satisfaction. Mulhall and colleagues have used the IIEF and the EDITS at 3-month intervals following implantation of IPPs. There was a continued improvement in scores for the IIEF and EDITS stabilized 9–12 months following surgery. All variables, including erection, ejaculation, orgasm, and overall sexual satisfaction, improved above baseline values at 1 year after surgery. However, at 3 months following surgery, the results were less satisfactory, suggesting that postoperative counseling and encouragement of patients are important to obtain ultimate satisfaction and positive outcomes at 9–12 months [13,69]. Trost and colleagues reviewed urologic and non-urologic cosmetic surgery literature to identify factors associated with patient satisfaction/dissatisfaction [70]. Factors associated with satisfaction included decreased preoperative expectations, favorable female partner sexual function, body mass index  $\leq 30$ , and the absence of Peyronie’s disease or prior prostatectomy. Determinants of dissatisfaction included perceived/actual loss of

penile length, decreased glanular engorgement, altered erectile/ejaculatory sensation, pain, diminished cosmetic outcome, difficulty with device function, partner dissatisfaction and perception of unnatural sensation, complications, and extent of alternative treatments offered. Furthermore, personality characteristics that could indicate psychologically challenging IPP patients include obsessive/compulsive tendencies, unrealistic expectations, patients undergoing revision surgery, those seeking multiple surgical opinions, feeling of entitlement, patients in denial of their prior erectile/sexual function and current disease status, or those with other psychiatric disorders [70].

#### Conclusions

Penile vein surgery should not be recommended. Penile revascularization procedures even executed in highly selected patients and performed by well-trained experienced surgeons result in a variable and unpredictable outcome. Penile prosthesis surgery is a safe and durable treatment option for male ED. Patient selection and counseling, strict adherence to antimicrobial prophylaxis, and surgical practice are paramount to ensure low complication rates and high patient satisfaction rate.

**Corresponding Author:** Eduardo B. Bertero, MD, Department of Urology, Section of Sexual Medicine, Hospital do Servidor Publico Estadual, Rua Vieira de Moraes, 420 cj 87, Sao Paulo, SP 04617000, Brazil. Tel: 5511-55424117; Fax: 5511-55429557; E-mail: urologia-sp@uol.com.br

*Conflict of Interest:* The authors report no conflicts of interest.

#### Statement of Authorship

##### Category 1

###### (a) Conception and Design

Eduardo B. Bertero; Dimas L. Antunes

###### (b) Acquisition of Data

Eduardo B. Bertero; Dimas L. Antunes

###### (c) Analysis and Interpretation of Data

Eduardo B. Bertero; Dimas L. Antunes

##### Category 2

###### (a) Drafting the Article

Eduardo B. Bertero; Dimas L. Antunes

###### (b) Revising It for Intellectual Content

Eduardo B. Bertero; Dimas L. Antunes

##### Category 3

###### (a) Final Approval of the Completed Article

Eduardo B. Bertero; Dimas L. Antunes

## References

- 1 Sohn M, Hatzinger M, Goldstein I. Standard operating procedures for vascular surgery in erectile dysfunction: Revascularization and venous procedures. *J Sex Med* 2013;10:172–9.
- 2 Montorsi F, Adaikan G, Becher E, Giuliano F, Khoury S, Lue T, Sharlip I, Althof SE, Andersson KE, Borck G, Broderick G, Burnett A, Buvat J, Dean J, Donatucci C, Hatzichristou D, Hellstrom W, Incrocci L, Jackson G, Kadioglu A, Levine L, Lewis RW, Maggi M, McCabe M, Mc Mahon CG, Montague D, Montorsi P, Mulhall J, Pfau J, Porst H, Ralph D, Rosen R, Rowland D, Sadeghi-Nejad H, Shabsigh R, Stief C, Vardi Y, Wallen K, Wasserman M. Summary of the recommendations on sexual dysfunctions in men. *J Sex Med* 2010;7:3572–88.
- 3 Fournier G, Juneman KP, Lue TF. Mechanism of venous occlusion during canine penile erection: An anatomic demonstration. *J Urol* 1987;137:163–7.
- 4 Sohn M, Martin-Morales A. Surgical treatment of erectile dysfunction. In: Porst JB, Buvat J, eds. *Standard practice in sexual medicine*. Hoboken, NJ: Wiley; 2006:126–48.
- 5 Hellstrom WJG, Montague DK, Moncada J, Carsson C, Minhas J, Faria G, Krishnamurti S. Implants, mechanical devices and vascular surgery for erectile dysfunction. *J Sex Med* 2010;7:501–23.
- 6 Michal V, Krama R, Pospichal J, Hejhal L. Direct arterial anastomosis on corpora cavernosa penis in the therapy of erectile impotence. *Rozhl Chir* 1973;52:587–90.
- 7 Dicks B, Bastuba M, Goldstein I. Penile revascularization—Contemporary update. *Asian J Androl* 2013;15:5–9.
- 8 Babaei AR, Safarinejad MR, Kolahi AA. Penile revascularization for erectile dysfunction: A systematic review and meta-analysis of effectiveness and complications. *J Urol* 2009;6:1–7.
- 9 Dabaja AA, Teloken P, Mulhall JP. A critical analysis of candidacy for penile revascularization. *J Sex Med* 2014;9:2327–32.
- 10 Munarriz R. Penile microvascular arterial bypass surgery: Indications, outcomes, and complications. *Sci World J* 2010;10:1556–65.
- 11 Lizza EF, Zorngiotti AW. Experience with the long-term effect of microsurgical penile revascularization. *Int J Impot Res* 1994;6:145–52.
- 12 Montague DK, Jarow JP, Broderick GA, Dmochowski RR, Heaton JP, Lue TF, Milbank AJ, Nehra A, Sharlip ID. Erectile dysfunction guideline update panel. Chapter 1: The management of erectile dysfunction: An AUA update. *J Urol* 2005;174:230–9.
- 13 Hatzimouratidis K, Eardley I, Giuliano F, Hatzichristou D, Moncada I, Salonia A, Vardi Y, Wespes E. European Urological Association guideline on male sexual dysfunction. 2014. Available at: [www.uroweb.org/guideline/male-sexual-dysfunction](http://www.uroweb.org/guideline/male-sexual-dysfunction) (accessed March 10, 2015).
- 14 Rosen RC, Riley A, Wagner G, Osterloh IH, Kirkpatrick J, Mishra A. The International Index of Erectile Function (IIEF): A multidimensional scale for assessment of erectile dysfunction. *Urology* 1997;49:822–30.
- 15 Kawanishi Y, Kimura K, Nakanishi R, Kojima K, Numata A. Penile revascularization surgery for arteriogenic erectile dysfunction: The long-term efficacy rate calculated by survival analysis. *BJU Int* 2004;94:361–8.
- 16 Munarriz R, Uberoi J, Fantini G, Martinez D, Lee C. Microvascular arterial bypass surgery: Long-term outcomes using validated instruments. *J Urol* 2009;182:643–8.
- 17 Manning M, Jünemann KP, Scheepe JR, Braun P, Krautschick A, Alken P. Long-term followup and selection criteria for penile revascularization in erectile failure. *J Urol* 1998;5:1680–4.
- 18 Pavlinec JG, Hakky TS, Yang C, Massis K, Munarriz R, Carrion RE. Penile artery shunt syndrome: A novel cause of erectile dysfunction after penile revascularization surgery. *J Sex Med* 2014;9:2338–41.
- 19 Oberlin DT, Matulewicz RS, Bachrach L, Hofer MD, Brannigan RE, Flury SC. National practice patterns for treatment of erectile dysfunction with penile prosthesis implantation. *J Urol* 2014;193:2040–4.
- 20 Wilson SK, Cleves M, Delk JR 2nd. Long-term results with Hydroflex and Dynaflex penile prostheses: Device survival comparison to multicomponent inflatables. *J Urol* 1996;5:1621–3.
- 21 Dhabuwala C, Sheth S, Zamzow B. Infection rates of rifampin/gentamicin-coated Titan Coloplast penile implants. Comparison with Inhibizone-impregnated AMS penile implants. *J Sex Med* 2011;1:315–20.
- 22 Carson CC. Diagnosis, treatment and prevention of penile prosthesis infection. *Int J Impot Res* 2003;15(suppl 5):S139–46.
- 23 Hellstrom WJG, Hyun JS, Human L, Sanabria JA, Bivalacqua TJ, Leungwattanakij S. Antimicrobial activity of antibiotic-soaked, resist(-coated Bioflex). *Int J Impot Res* 2003;15:18–21.
- 24 Montorsi F, Dehó F, Salonia A, Briganti AA, Bua L, Fantini GV, Gallina A, Saccá A, Mirone V, Rigatti P. Penile implants in the era of oral drug treatment for erectile dysfunction. *BJU Int* 2004;94:745–51.
- 25 Tran SN, Wirth GJ, Mayor G, Rollini C, Bianchi-Demicheli F, Iselin CE. Prospective evaluation of early postoperative male and female sexual function after radical prostatectomy with erectile nerves preservation. *Int J Impot Res* 2015;27:69–74.
- 26 Esen B, Kahvecioglu S, Atay AE, Ozgen G, Okumus MM, Seyahi N, Sit D, Kadioglu P. Evaluation of relationship between sexual functions, depression and quality of life in patients with chronic kidney disease at predialysis stage. *Ren Fail* 2015;2:262–7.
- 27 Montague DK. Penile prosthesis implantation in the era of medical treatment for erectile dysfunction. *Urol Clin North Am* 2011;38:217–25.
- 28 Montague DK, Angermeier KW. Future considerations: Advances in the surgical management of erectile dysfunction. *Int J Impot Res* 2002;12(suppl 4):140–3.
- 29 Hinds PR, Wilson SK, Sadeghi-Nejad H. Dilemmas of inflatable penile prosthesis revision surgery: What practices achieve the best outcomes and the lowest infection rates? (CME). *J Sex Med* 2012;9:2483–91.
- 30 Wilson SK, Delk JR 2nd. Inflatable penile implant infection: Predisposing factors and treatment suggestions. *J Urol* 1995;153(3 Pt 1):659–61.
- 31 Wilson SK, Carson CC, Cleves MA, Delk JR. Quantifying risks of penile prosthesis infection with elevated glycosylated hemoglobin. *J Urol* 1998;159:1537–40.
- 32 Bishop JR, Moul JW, Sihelnik SA, Peppas DS, Gormley TS, McLeod DG. Use of glycosylated hemoglobin to identify diabetics at high risk for penile periprosthetic infections. *J Urol* 1992;147:386–8.
- 33 Mulcahy JJ, Austoni E, Barada JH, Choi HK, Hellstrom JG, Krishnamurti S, Moncada I, Schultheiss D, Sohn M, Wessells H. The penile implant for erectile dysfunction. *J Sex Med* 2004;1:98–109.
- 34 Wilson SK, Henry GD, Delk JR Jr, Cleves MA. The mentor alpha 1 penile prosthesis with reservoir lock-out valve: Effective prevention of auto-inflation with improved capability for ectopic reservoir placement. *J Urol* 2002;168(4 Pt 1):1475–8.
- 35 Rossier AB, Fam BA. Indication and results of semirigid penile prostheses in spinal cord injury patients: Long-term followup. *J Urol* 1984;131:59–62.

- 36 Dos Reis JM, Glina S, Da Silva MF, Furlan V. Penile prosthesis surgery with the patient under local regional anesthesia. *J Urol* 1993;150:1179–81.
- 37 Katz DJ, Stember DS, Nelson CJ, Mulhall JP. Perioperative prevention of penile prosthesis infection: Practice patterns among surgeons of SMSNA and ISSM. *J Sex Med* 2012;9:1705–12.
- 38 D'Amico DF, Parimbelli P, Ruffolo C. Antibiotic prophylaxis in clean surgery: Breast surgery and hernia repair. *J Chemother* 2001;13:108–11.
- 39 Zibari GB, Gadallah MF, Landreneau M, McMillan R, Bridges RM, Costley K, Work J, McDonald JC. Preoperative vancomycin prophylaxis decreases incidence of postoperative hemodialysis vascular access infections. *Am J Kidney Dis* 1997;30:343–8.
- 40 Hill C, Flamant R, Mazas F, Evrard J. Prophylactic cefazolin vs. placebo in total hip replacement: Report of a multicentre double-blind randomised trial. *Lancet* 1981;317:795–7.
- 41 Schwartz BF, Swanzy S, Thrasher JB. A randomized prospective comparison of antibiotic tissue levels in the corpora cavernosa of patients undergoing penile prosthesis implantation using gentamicin plus cefazolin vs. an oral fluoroquinolone for prophylaxis. *J Urol* 1996;156:991–4.
- 42 Wosnitzer MS, Greenfield JM. Antibiotic patterns with inflatable penile prosthesis insertion. *J Sex Med* 2011;8:1521–8.
- 43 Eid JF, Wilson SK, Cleves M, Salem EA. Coated implants and “no touch” surgical technique decreases risk of infection in inflatable penile prosthesis implantation to 0.46%. *Urology* 2012;79:1310–15.
- 44 Kaufman JJ. Penile prosthetic surgery under local anesthesia. *J Urol* 1982;28:1190–1.
- 45 Mulcahy JJ. Implants, mechanical devices and vascular surgery for erectile dysfunction. In: Lue TF, Basson R, Rosen R, Giuliano F, Khoury S, Montorsi F, eds. *Sexual medicine: Sexual dysfunctions in men and women*. Paris: ©Health Publications; 2004:469–98, chapter 14. 2nd International Consultation on Sexual Dysfunctions.
- 46 Montague DK, Angermeier KW. Surgical approaches for penile prosthesis implantation: Penoscrotal vs. infrapubic. *Int J Impot Res* 2003;15(suppl 5):134–5.
- 47 Trost LW, Boonjindasup AG, Hellstrom WJ. Comparison of infrapubic vs. transcrotal approaches for inflatable penile prosthesis placement: A multi-institution report. *Int J Impot Res* 2014;27:86–9.
- 48 Mulhall JP, Jahoda A, Aviv N, Valenzuela R, Parker M. The impact of sildenafil citrate on sexual satisfaction profiles in men with a penile prosthesis in situ. *BJU Int* 2004;93:97–9.
- 49 Chew KK, Stuckey BGA. Use of transurethral alprostadil (MUSE) (prostaglandin E1) for glans tumescence in a patient with penile prosthesis. *Int J Impot Res* 2000;12:195–6.
- 50 Anele UA, Le BV, Burnett AL. Suprapubic cystostomy for the management of urethral injuries during penile prosthesis implantation. *Sex Med* 2014;2:178–81.
- 51 Tran CN, Boncher N, Montague DK, Angermeier KW. Erosion of inflatable penile prosthesis reservoir into neobladder. *J Sex Med* 2013;10:2343–6.
- 52 Eldefrawy A, Kava BR. An unusual complication during inflatable penile prosthesis implantation. *Urology* 2010;76:847. doi: 10.1016/j.urology.2009.11.034; [Epub 2010 Feb 6].
- 53 Mulhall JP, Kim FJ. Reconstructing penile supersonic trans-porter (SST) deformity using glanulopexy (glans fixation). *Urology* 2001;57:1160–2.
- 54 Montague DK, Angermeier KW. Cylinder sizing: Less is more. *Int J Impot Res* 2003;15(suppl 5):S132–3.
- 55 Karpman E, Henry G. Capsular contraction with s-shaped deformity of nonlength-expanding inflatable penile prosthesis cylinders: Management and prevention strategies. *Sex Med* 2013;1:95–8. doi: 10.1002/sm.2.14.
- 56 Carson CC, Mulcahy JJ, Govier FE. Efficacy, safety and patient satisfaction outcomes of the AMS 700CX inflatable penile prosthesis: Results of a long-term multicenter study. AMS 700CX study group. *J Urol* 2000;164:376–80.
- 57 Wilson SK, Cleves MA, Delk JR 2nd. Comparison of mechanical reliability of original and enhanced Mentor Alpha I penile prosthesis. *J Urol* 1999;162(3 Pt 1):715–8.
- 58 Trost LW, McCaslin R, Linder B, Hellstrom WJ. Long-term outcomes of penile prostheses for the treatment of erectile dysfunction. *Expert Rev Med Devices* 2013;10:353–66.
- 59 Garber BB, Khurgin JL, Stember DS, Perito PE. Pseudo-malfunction of the Coloplast Titan inflatable penile prosthesis one-touch release pump. *Urology* 2014;84:857–9.
- 60 Carson CC 3rd. Efficacy of antibiotic impregnation of inflatable penile prostheses in decreasing infection in original implants. *J Urol* 2004;171:1611–4.
- 61 Wolter CE, Hellstrom WJ. The hydrophilic-coated inflatable penile prosthesis: 1-year experience. *J Sex Med* 2004;1:221–4.
- 62 Carson CC 3rd, Mulcahy JJ, Harsch MR. Long-term infection outcomes after original antibiotic impregnated inflatable penile prosthesis implants: Up to 7.7 years of follow-up. *J Urol* 2011;185:614–8.
- 63 Serefoglu EC, Mandava SH, Gokce A, Chouhan JD, Wilson SK, Hellstrom WJG. Long-term revision rate due to infection in hydrophilic-coated inflatable penile prostheses: 11-year follow-up. *J Sex Med* 2012;9:2182–6.
- 64 Mulcahy JJ. Current approach to the treatment of penile implant infections. *Ther Adv Urol* 2010;2:69–75.
- 65 Swords K, Martinez DR, Lockhart JL, Carrion R. A preliminary report on the usage of an intracorporeal antibiotic cast with synthetic high purity CaSO4 for the treatment of infected penile implant. *J Sex Med* 2013;10:1162–9.
- 66 Grewal S, Vetter J, Brandes SB, Strobe SA. A population-based analysis of contemporary rates of reoperation for penile prosthesis procedures. *Urology* 2014;84:112–6.
- 67 Wilson SK. Reimplantation of inflatable penile prosthesis into scarred corporeal bodies. *Int J Impot Res* 2003;15(suppl 5):125–8.
- 68 Caraceni E, Utizi L. A questionnaire for the evaluation of quality of life after penile prosthesis implant: Quality of life and sexuality with penile prosthesis (QoLSPP): To what extent does the implant affect the patient's life? *J Sex Med* 2014;11:1005–12.
- 69 Mulhall JP, Ahmed A, Branch J, Parker M. Serial assessment of efficacy and satisfaction profiles following penile prosthesis surgery. *J Urol* 2003;169:1429–33.
- 70 Trost LW, Baum N, Hellstrom WJ. Managing the difficult penile prosthesis patient. *J Sex Med* 2013;10:893–906.